Neuromuscular Therapy American version™

Hand and Forearm Pain

Judith DeLany, LMT

Published by:

NMT Center
900 14th Avenue North
St. Petersburg, FL 33705
(727) 821-7167
fax: (727) 822-0643
nmtcenter @aol.com
www.nmtcenter.com

Anterior Forearm - "Misc."

Innervation

Radial, ulnar, and median nerves (C5-T1)

Brachioradialis: proximal 2/3 of lateral supracondylar ridge of the humerus and intermuscular septum to the styloid process of the radius; Supinator: supinator crest of the ulna, lateral epicondyle of the humerus and ligaments and joint capsule of the elbow to the lateral surface of the proximal third of the radius; Pronator teres: medial epicondyle of humerus, medial intermuscular septum and coronoid process of the ulna to the pronator tuberosity of the radius; Pronator quadratus: anterior surface of the ulna to anterior surface of the radius; See the following two pages for additional muscle details.

Precautions**:** Treat these muscles in carpal tunnel syndrome, however, be cautious of the radial artery and median nerve at the wrist.

Preparation: The person is supine or sits in a chair. The non-lubricated arm is semi-supinated and supported on the table. The practitioner stands or is seated.

Step 1: With the person's forearm in a semi-supinated position, grasp the **brachioradialis** and apply compression at thumb width intervals from the humeral attachment to as far distally as it can be grasped. Repeat several times if tender. A deeper grasp will also treat the **extensor carpi radialis longus** and **brevis**, and (possibly) **supinator**.

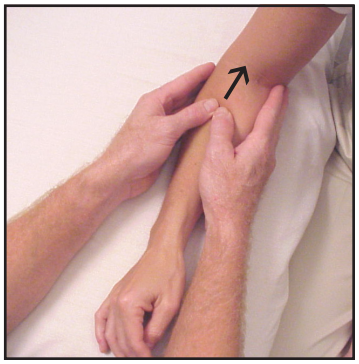

Step 2: Apply lubricated gliding strokes to **brachioradialis**. Deeper pressure addresses **extensor carpi radialis longus** and **brevis**, and **supinator**.

Step 3: Displace the brachioradialis and extensor carpi muscles laterally and glide the thumb directly on **supinator**. Repeat on the medial side.

Step 4: Supinate the forearm and apply gliding strokes from the lateral wrist (scaphoid bone) to the elbow crease repeatedly to treat portions of **brachioradialis**, **pronator quadratus**, **flexor digitorum superficialis**, **flexor pollicis longus**, and **pronator teres**.

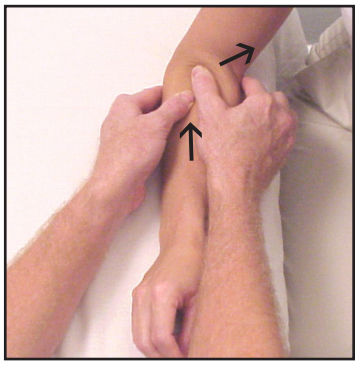

Continued on next page.

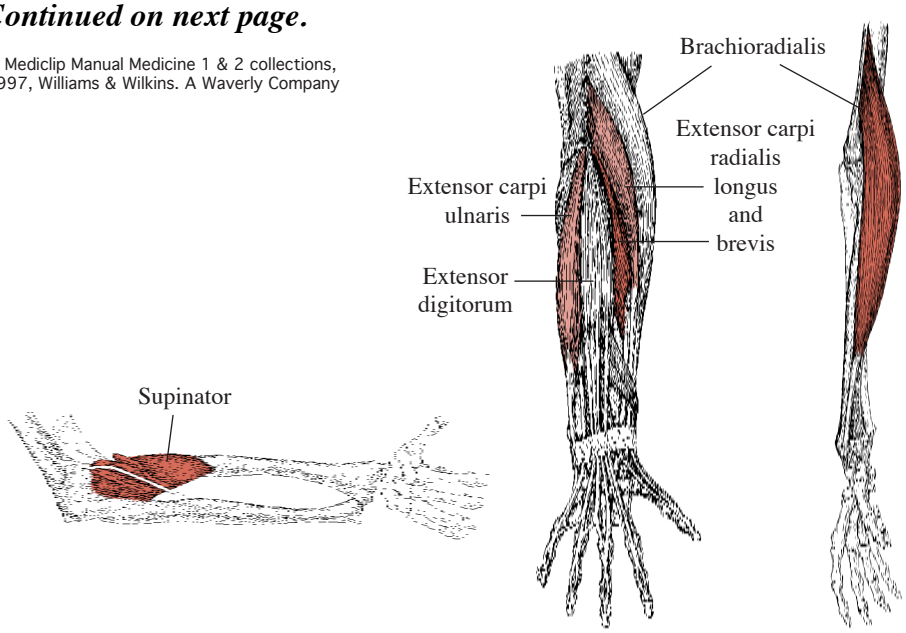

Anterior Forearm - "The Flexors"

Innervation

Radial, ulnar, and median nerves (C5-T1)

Palmaris longus: medial epicondyle to palmar fascia and transverse carpal ligament; Flexor carpi radialis: medial epicondyle of humerus, antebrachial fascia and intermuscular septa to the base of 2nd and 3rd metacarpals; Flexor carpi ulnaris: medial epicondyle of humerus and olecranon to the pisiform, hamate and 5th metacarpal; Flexor digitorum superficialis: medial epicondyle of humerus, coronoid process of elbow and oblique line of radius through the carpal canal to end in four tendons each attaching to a middle phalanx; Flexor digitorum profundus: ulna, interosseous membrane and coronoid process of the elbow to become four tendons, each attaching to a distal phalanx

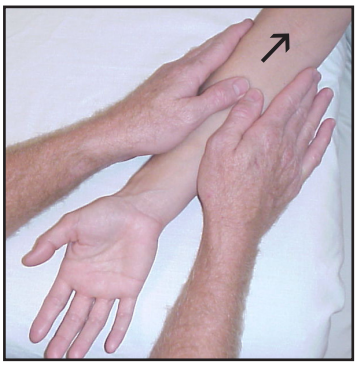

Continued from previous page.

Step 5: Move the thumbs medially and continue the gliding strokes on the next strip of the anterior forearm from the wrist to the elbow crease to treat **flexor carpi radialis**, **palmaris longus**, **flexor digitorum superficialis** and **pronator teres**. Deeper pressure will treat **pronator quadratus** and **flexor digitorum profundus**. Do not press deeply at the wrist as the radial artery and median nerve lie deep to the tendons. Continue gliding in strips until the entire anterior forearm has been treated.

Step 6: Transverse snapping palpation can be applied to the **pronator teres**, which courses diagonally just distal to the crease of the elbow.

Step 7: If appropriate, apply friction to the attachment of the **common flexor tendon** on the medial epicondyle of the humerus where 5 muscles originate (**pronator teres**, **palmaris longus**, **flexor carpi ulnaris**, **flexor carpi radialis** and **flexor digitorum superficialis**).

Note: The supinator can entrap the deep branch of radial nerve.

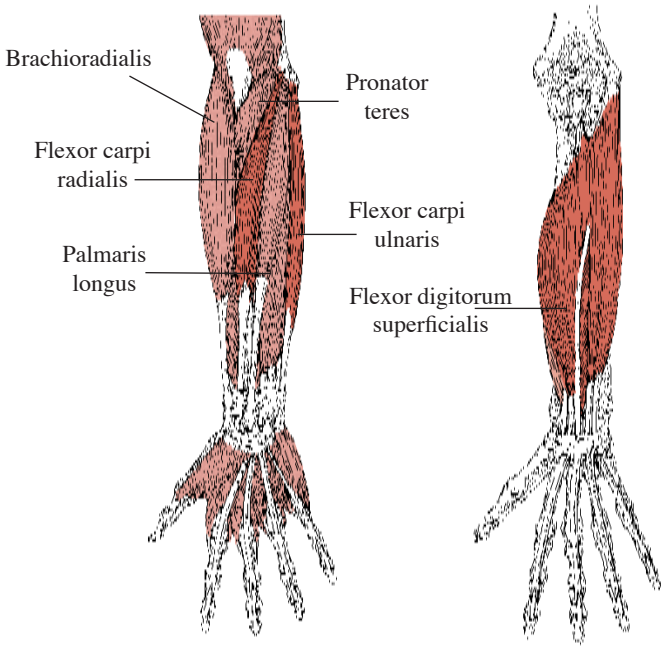

Posterior Forearm - "The Extensors"

Innervation

Radial, ulnar, and median nerves (C5-T1)

Extensor carpi radialis longus: humerus and intermuscular septum to the base of the 2nd metacarpal; Extensor carpi radialis brevis: lateral epicondyle to the base of the 2nd and 3rd metacarpals ; Extensor digitorum: lateral epicondyle, antebrachial fascia and intermuscular septa to the middle phalanx or base of the distal phalanx of 2nd–5th fingers; Extensor carpi ulnaris: common extensor tendon and posterior border of ulna to base of 5th metacarpal

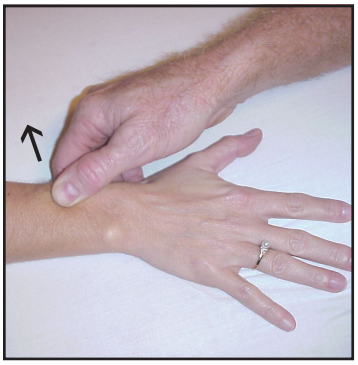

Precautions: Avoid the ulnar and radial nerves at the elbow.

Preparation: The patient is in the same position as the previous page and with the forearm pronated.

Step 1: Apply lubricated gliding strokes repeatedly from the styloid process of the radius to the lateral epicondyle of the humerus to treat **abductor pollicis longus**, **extensor policis brevis** and **extensor digitorum**.

Step 2: Apply gliding strokes between the radius and ulna from the wrist to the lateral epicondyle of the humerus. Repeat 6-8 times to treat the **extensor digiti minimi, extensor carpi ulnaris, extensor pollicis longus, extensor digitorum,** and **extensor indicus**.

Step 3: Glide the thumbs 6-8 times on the lateral portion of the posterior forearm from the styloid process of the ulna to the lateral epicondyle of the humerus to treat **extensor carpi ulnaris**, **anconeus** and portions of **brachioradialis**, **extensor carpi radialis longus** and **brevis**, and (possibly) **supinator**. Unidirectional transverse friction (snapping palpation) can be applied to the muscle bellies and tendons, if appropriate.

Step 4: If not excessively tender, friction the attachment of the **common extensor tendon** on the lateral epicondyle of the humerus where 6 muscles attach (**extensor carpi radialis longus** and **brevis, extensor digitorum, extensor carpi ulnaris, supinator** and **anconeus**). This palpable overlapping of tissues can be easily grasped, compressed and manipulated between the thumb and fingers.

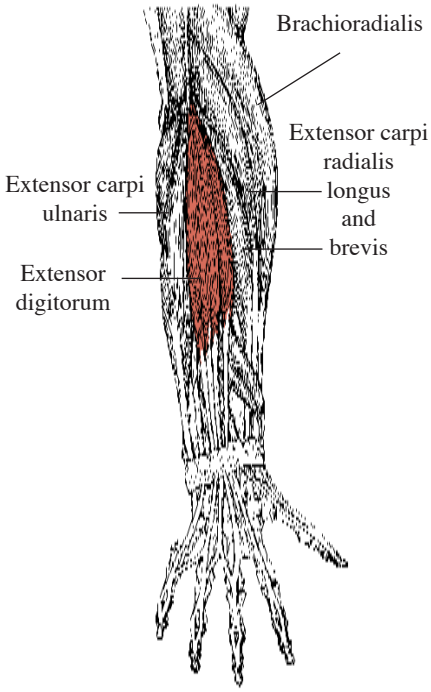

Palmar and Dorsal Hand

Innervation

Radial, ulnar, and median nerves (C5-T1)

For the lengthy list of muscles associated with fine finger and thumb control, see *Clinical Application of Neuromuscular Techniques, Vol. 1, The Upper Body* or any other detailed anatomy text.

Precautions:

- ✳ Do not treat when inflamed arthritis is present.
- ✳ Avoid pressure directly over wrist.
- ✳ Do not treat the tendons when swelling over the tendons is present.

Preparation: Practitioner and patient are positioned as in the previous two pages and with the patient's hand supinated. The beveled pressure bar is needed.

Step 1: Compress the thenar eminence to treat the **abductor pollicis brevis**, **flexor pollicis brevis** and **opponens pollicis**.

Step 2: Compress the "web" between the thumb and index finger to treat the **adductor pollicis**.

Step 3: Compress hypothenar eminence to treat the **abductor minimi**, **flexor digiti minimi brevis** and **opponens digiti minimi** muscles.

Step 4: Apply myofascial spreading to the **palmar fascia**.

Step 5: Place the beveled pressure bar tip between the metacarpal bones and use friction to treat the **lumbricals** and **palmar interossei**.

Step 6: Pronate the hand and use the beveled pressure bar tip to apply friction between of the metacarpal bones to treat the **dorsal interossei**.

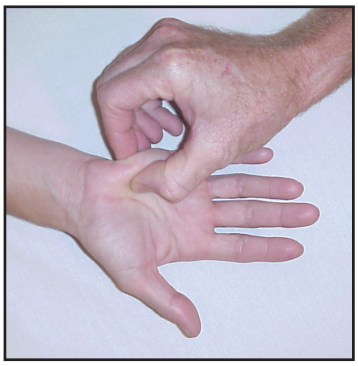

Step 7: The palmar surface, digital tendons and interphalangeal joints of each finger can be scraped with the beveled pressure bar tip provided that inflammation or infection is not present.

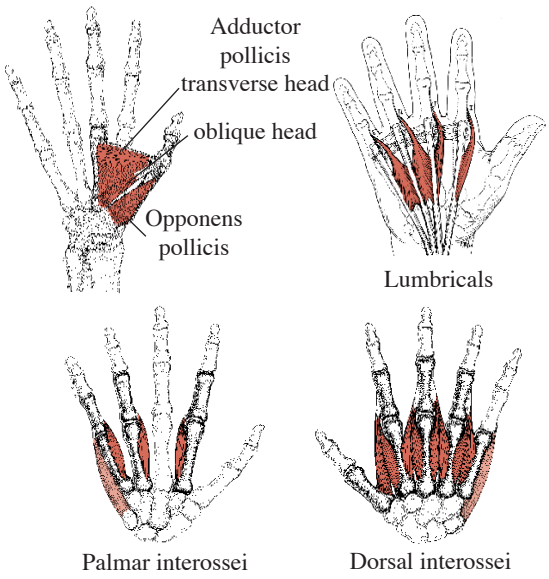

Trigger Point Target Zones into Forearm and Hand

The trigger points and target zones noted are some of the most common patterns for this area but not the only possible patterns of referral.

Trigger point target zone illustrations are from the Mediclip Manual Medicine 1 & 2 collections, 1997, Williams & Wilkins. A Waverly Company.

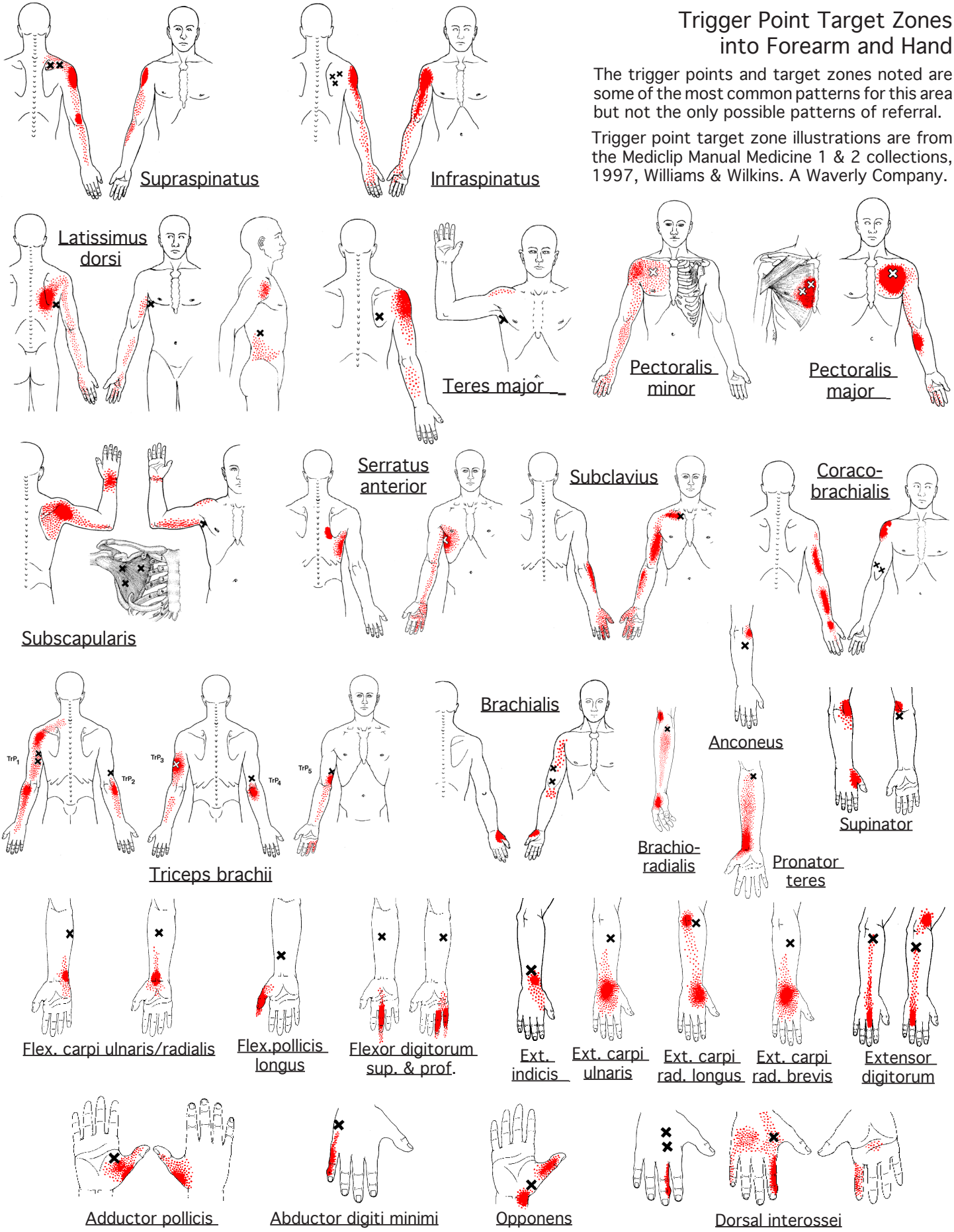

Suggested Study List for NMT

Baldry P 2005 Acupuncture, trigger points and musculoskeletal pain, 3rd edn. Churchill Livingstone, Edinburgh

Cailliet R 2004 Medical orthopedics: conservative management of muskeletal impairments. AMA Press
1996 Soft tissue pain and disability, 3d edn. F A Davis, Philadelphia

Clemente C 1987 Anatomy: a regional atlas of the human body, 3rd edn. Urban & Schwarzenberg, Baltimore

Chaitow L, DeLany J 2008 Clinical application of neuromuscular techniques, vol. 1, the upper body. Churchill Livingstone, Edinburgh (2nd edn

Chaitow L, DeLany J 2011 Clinical application of neuromuscular techniques, vol. 2, the lower body. Churchill Livingstone, Edinburgh

DeLany J 2010 American neuromuscular therapy. In: Chaitow L Modern neuromuscular techniques, 3rd edn., Chapter 10. Churchill Livingstone, Edinburgh

Drake et al 2009 Gray's anatomy for students, 2nd edn. Churchill Livinstone, Philadelphia

Gray's anatomy 2008 (40th edn) Churchill Livingstone, Edinburgh

Hoppenfeld S 1976 Physical examination of the spine and extremities. Appleton & Lange, Norwalk, CT

Juhan D 1998 Job's body, expanded edn. Station Hill Press, Barrytown, NY

Levangie P, Norkin C 2011 Joint structure and function: a comprehensive analysis, 5th edn. F A Davis, Philadelphia

Lowe W 2009 Orthopedic massage: theory and practice, 2nd edn. Mosby, Edinburgh

Lowe W 2006 Orthopedic assessment in massage therapy. Daviau Scott, Sisters OR

Mense S, Simons D 2001 Muscle pain: understanding its nature diagnosis and treatment. LWW, Philadelphia

Myers, T 2008 Anatomy Trains, 2nd edn. Churchill Livingstone, Edinburgh

Netter F 2006 Atlas of Human Anatomy, 4th edn. Saunders Elsevier, Philadelphia

Petty N 2006 Neuromusculoskeletal examination and assessment, 3rd edn. Churchill Livingstone, Edinburgh

Platzer W 2009 Color atlas and textbook of human anatomy, Vol 1: locomotor system, 6th edn. Georg Thieme Verlag, Stuttgart

Simons D, Travell J, Simons L 1999 Myofascial pain and dysfunction: the trigger point manual, vol. I, upper half of body, 2nd edn. Williams & Wilkins, Baltimore

Travell J, Simons D 1992 Myofascial pain and dysfunction: the trigger point manual, vol. 2, lower half of body. Williams & Wilkins, Baltimore

Vleeming A, Mooney V, Stoeckart R (eds) 2007 Movement, stability and lumbopelvic pain, 2nd edn. Churchill Livingstone, Edinburgh

Websites Worthy of a Visit

www.drlowe.com - fibromyalgia; discussion of thyroid
www.bodyworkmovementtherapies.com - Journal of Bodywork and Movement Therapies
www.fleshandbones.com - anatomy, games, illustrations
www.getbodysmart.com - free site anatomy with details
www.howstuffworks.com - many topics, including body
www.johnleemd.com - hormonal therapy
www.medlineplus.gov - medical library services
www.merckmanuals.com - access the Merck Manual
www.nlm.nih.gov - Nat'l Lib. of Medicine
www.nmtcenter.com - NMT American Version™
www.pdrhealth.com - physician's desk reference
www.sciencedirect.com - medical library services (fees)
www.scholar.google.com - academic articles on google
www.whonamedit.com - how items got names

Several articles discussing NMT American version™ are available as PDF documents at www.nmtcenter.com. Click on Article/Brochures button to access a number of support documents, including NMT Foundation Platform.pdf.